



Virtual Stress Testing of Regenerating Bone in Tibia Fractures

Presentation by: Joseph L. Petfield, MD ¹

Co-authors: Matthew Kluk, MD ²; Emily Shin, MD ²; Husain Bharmal, MD ²;
Paul Hoffman, BS ⁵; Tony Keaveny, PhD ^{3,5}; Wade Gordon, MD ²;
Wesley Jackson, PhD ³; Joseph R. Hsu, MD⁴; Leon Nesti, MD, PhD ²; Garry
Hayeck, PhD ⁵

¹Department of Orthopaedics and Rehabilitation, San Antonio Military Medical Center

²Department of Orthopaedic Surgery, Walter Reed National Military Medical Center

³ Department of Mechanical Engineering, University of California, Berkeley

⁴Department of Orthopaedic Surgery, Carolinas Medical Center

⁵O. N. Diagnostics, Berkeley, CA

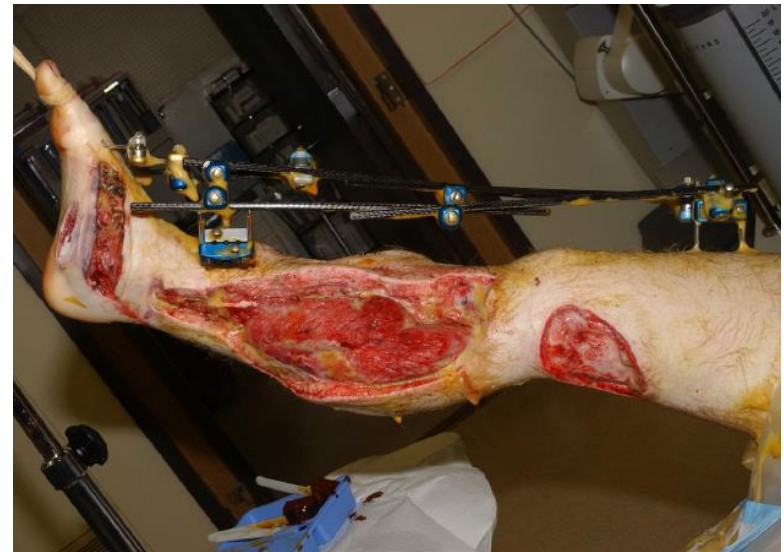
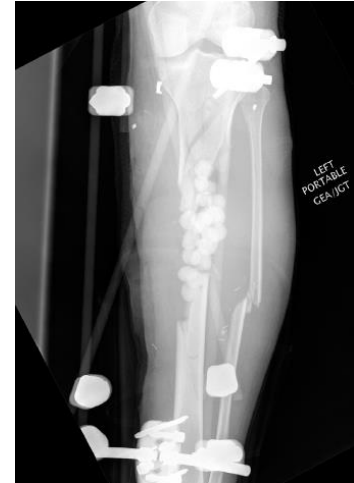
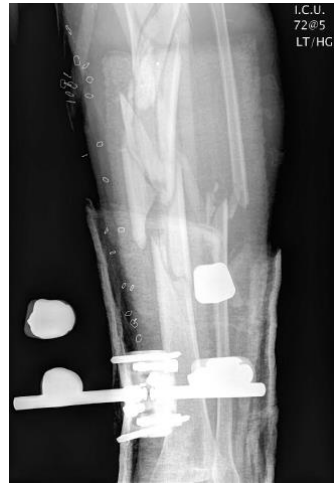
Disclosure

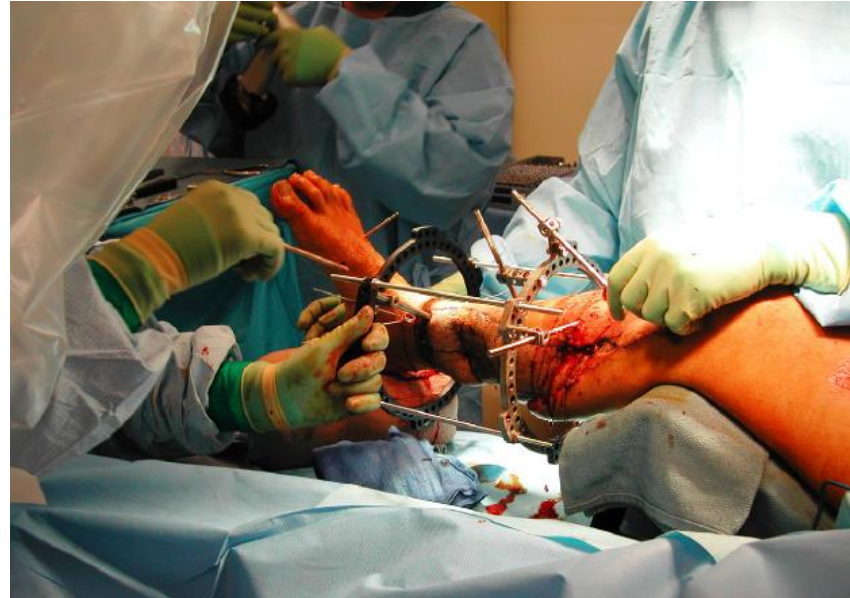- *The opinions or assertions contained herein are the private views of the author and are not to be construed as official or as reflecting the views of the Department of the Army or the Department of Defense.*
- *This study was conducted under a protocol reviewed and approved by the Brooke Army Medical Center Institutional Review Board and in accordance with the approved protocol.*
- *All patient photographs are used with permission*
- *Department of Defense Research Grant, Award Number W81XWH-10-2-0079*
- *Wesley Jackson, PhD: Henry M. Jackson Foundation*
- *Paul Hoffmann, BD: Employee, O.N. Diagnostics, L.L.C.*
- *Garry Hayeck, PhD: Previous Employee, O.N. Diagnostics, L.L.C.*
- ***Presenting Author: No disclosures***

Introduction

- Musculoskeletal injuries
 - nearly 2/3 of combat wounds (54-65%)
- Comminuted, open fractures of lower extremity long bones
- Clinical Decision:
 - Limb Salvage
 - Amputation



- Limb Salvage: Circular external fixation
 - Early Weight Bearing
 - Infection
 - Soft tissue management
- Long-Term care plan
 - Fixator removal
- Clinical event → Amputation vs. Continued Limb Salvage
- Assessment of Bone healing
 - Variable, Subjective

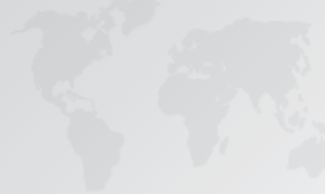

Variability in the Assessment of Fracture-Healing in Orthopaedic Trauma Studies

By Luis A. Corrales, MD, Saam Morshed, MD, MPH,
Mohit Bhandari, MD, MSc, FRCSC, and Theodore Miclau III, MD

“We found a lack of consensus with regard to the definition of fracture healing”

Keeling, J.J., D.E. Gwinn, S.M. Tintle, R.C. Andersen, and F.X. McGuigan, Short-term outcomes of severe open wartime tibial fractures treated with ring external fixation. *J Bone Joint Surg Am*, 2008. 90(12): p. 2643-51.



- Virtual Stress Testing

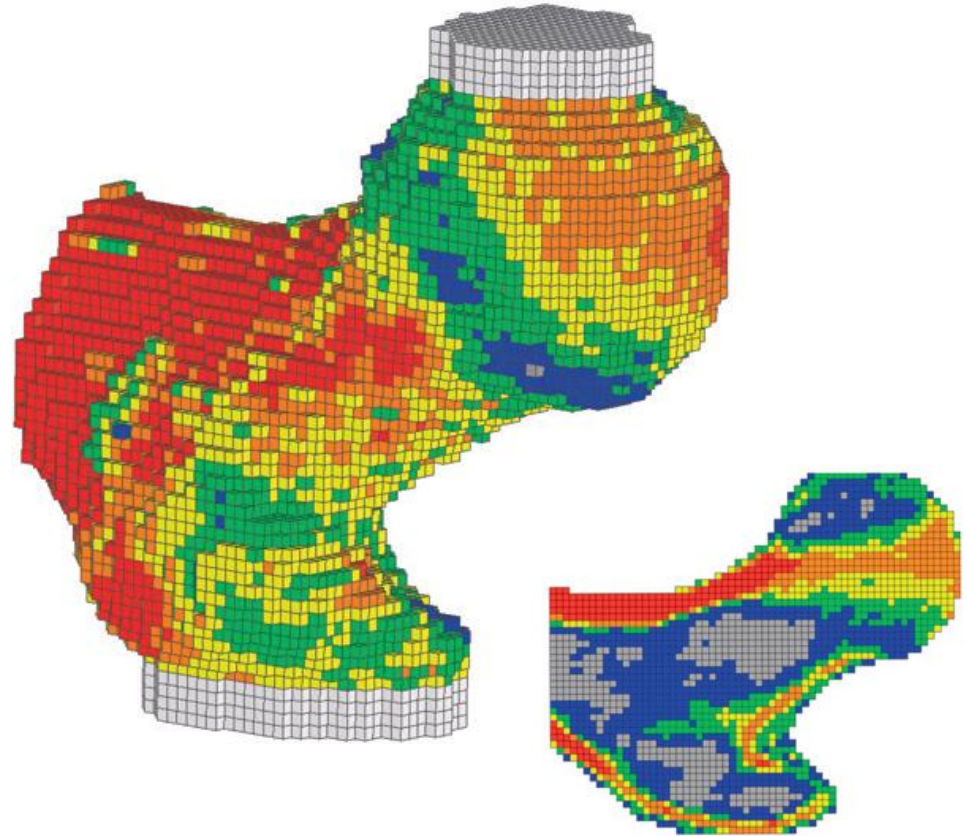
- 3 Dimensional Imaging
- Biomechanical Principles

- Finite Element Analysis

- Quantitative assessment

- Other applications:

- Osteoporosis
- Spinal fusions



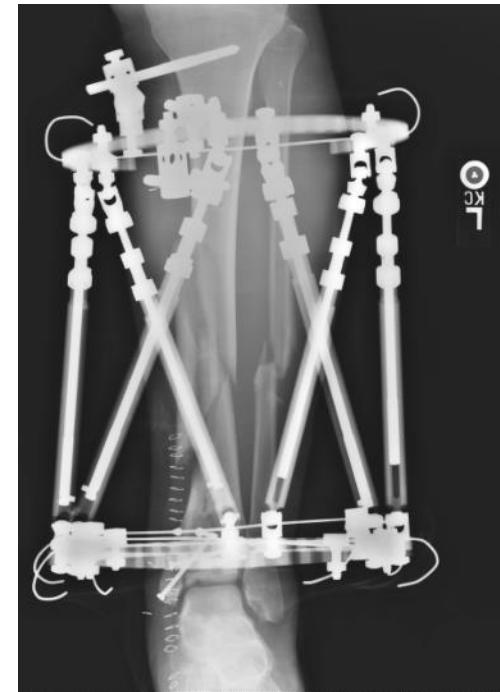
Orwoll, E.S., L.M. Marshall, C.M. Nielson, S.R. Cummings, J. Lapidus, J.A. Cauley, K. Ensrud, N. Lane, P.R. Hoffmann, D.L. Kopperdahl, and T.M. Keaveny, Finite element analysis of the proximal femur and hip fracture risk in older men. *J Bone Miner Res*, 2009. 24(3): p. 475-83.



Hypothesis

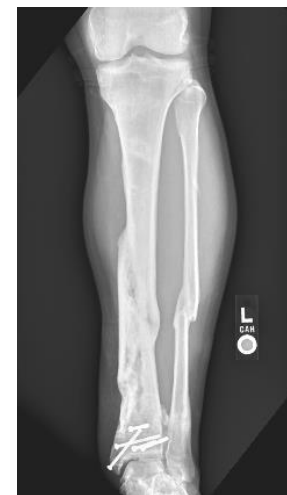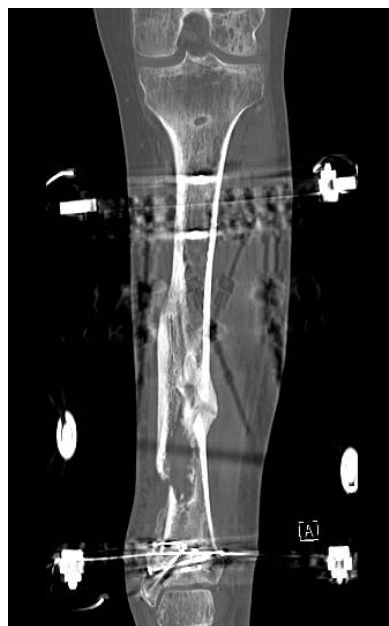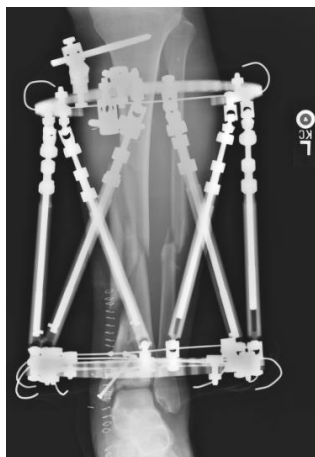
Virtual Stress Testing can be applied to tibia fractures to identify patients who will experience a “clinical event” (re-fracture, malunion, need for surgical revision) if their fixation hardware were removed

- Retrospective review of military beneficiaries
 - San Antonio Military Medical Center
 - Walter Reed National Military Medical Center
- Surgical Database search
- Military patients who had undergone surgical treatment of a fractured tibia with a circular external fixator
 - CT scan of their fracture 2-4 weeks prior to removal or dynamization of their fixation device



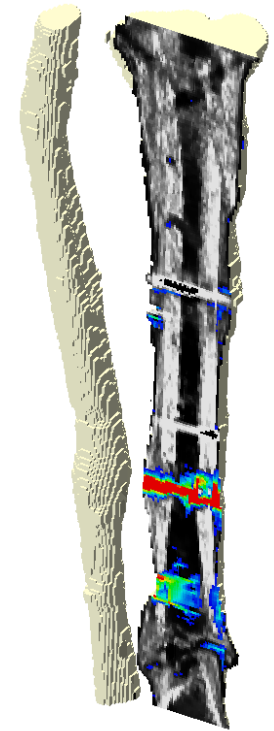
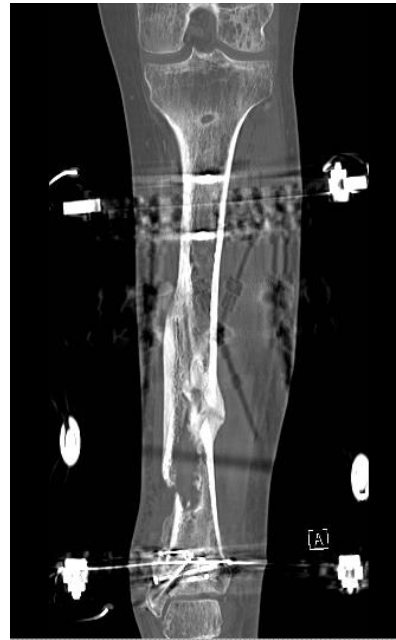Methods

- Clinical Course
- Clinical Event?
 - Refracture
 - Progressive malunion
 - Retightening
 - Unanticipated bone grafting
- CT scans → Virtual stress test



Methods

- Patient-specific finite element models
- Virtual stress testing of applied loads:
 - Axial Compression
 - Bending
 - Area of failed tissue
- Statistical analysis



Results: Patient Demographics

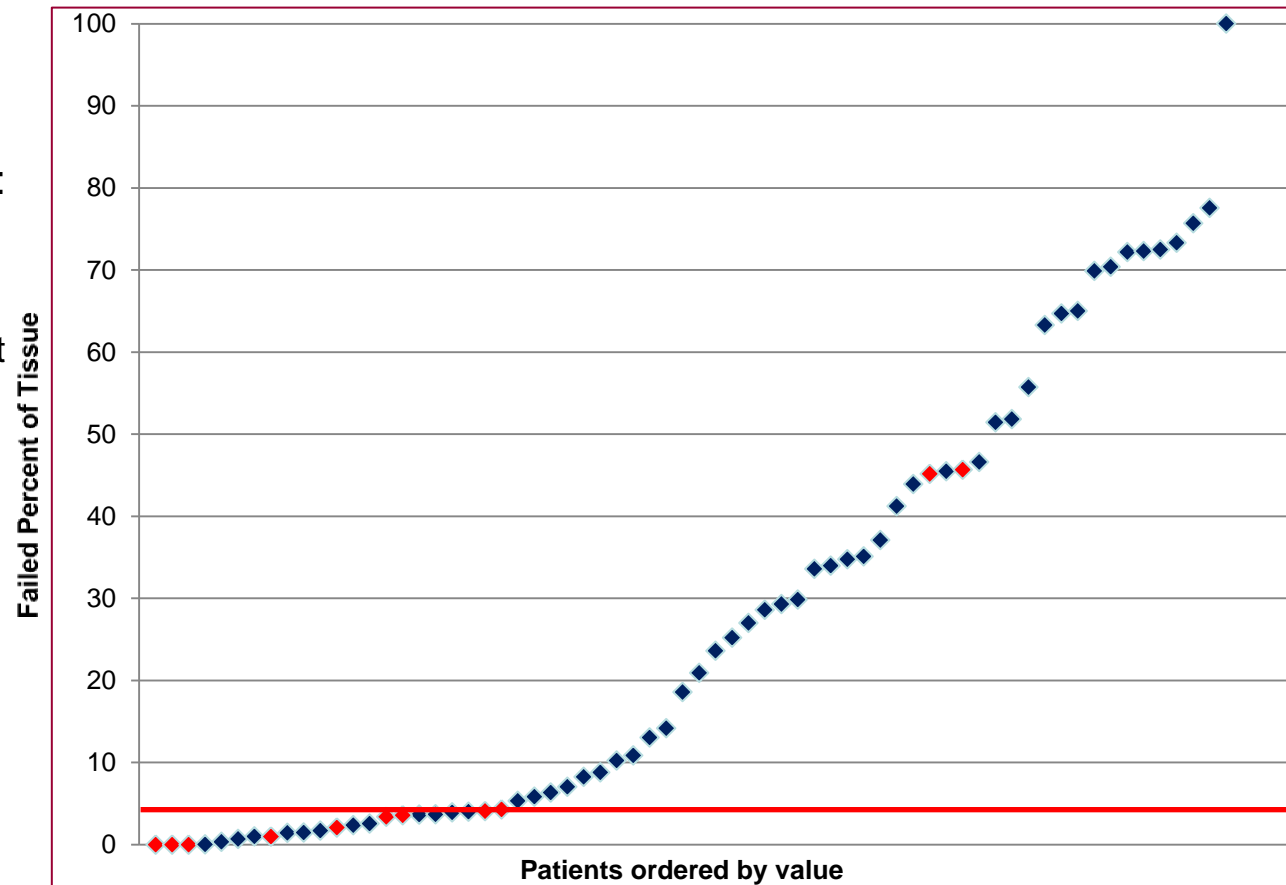
- 66 included patients
 - Mean age 28.8 years
 - 65 male
 - 95% Open fractures (63/66)
 - 36% tobacco use (24 patients)
- Mean time in frame: 274 days
- 17 complications:
 - 5 Deep infection
 - 10 Osteomyelitis
 - 2 Ring breakage





Results

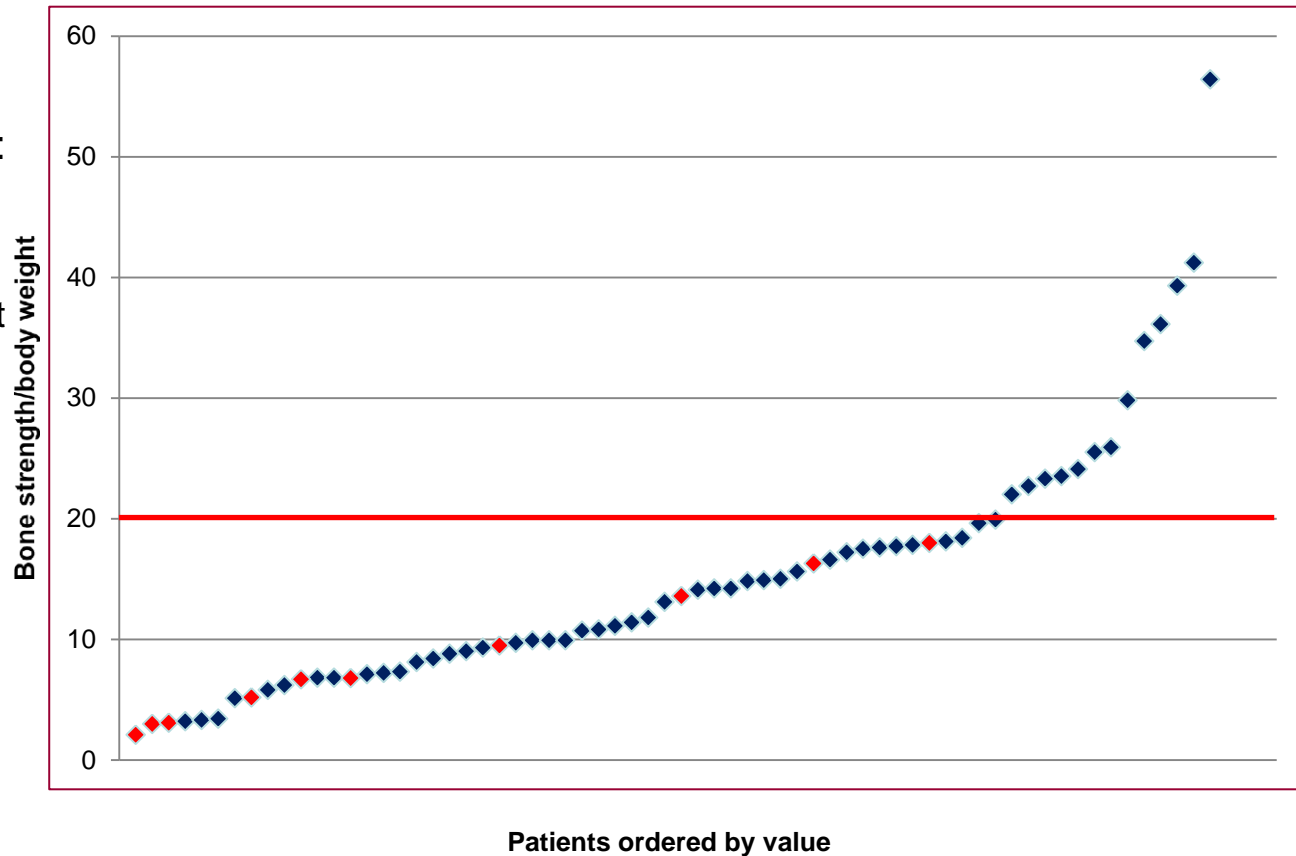
- Patients with clinical events: 11 (16.7%)
 - 6 progressive malunions
 - 4 unanticipated bone graft
 - 1 refracture
- Virtual stress test data
 - Percent Area of Failed Tissue
 - Axial Compression



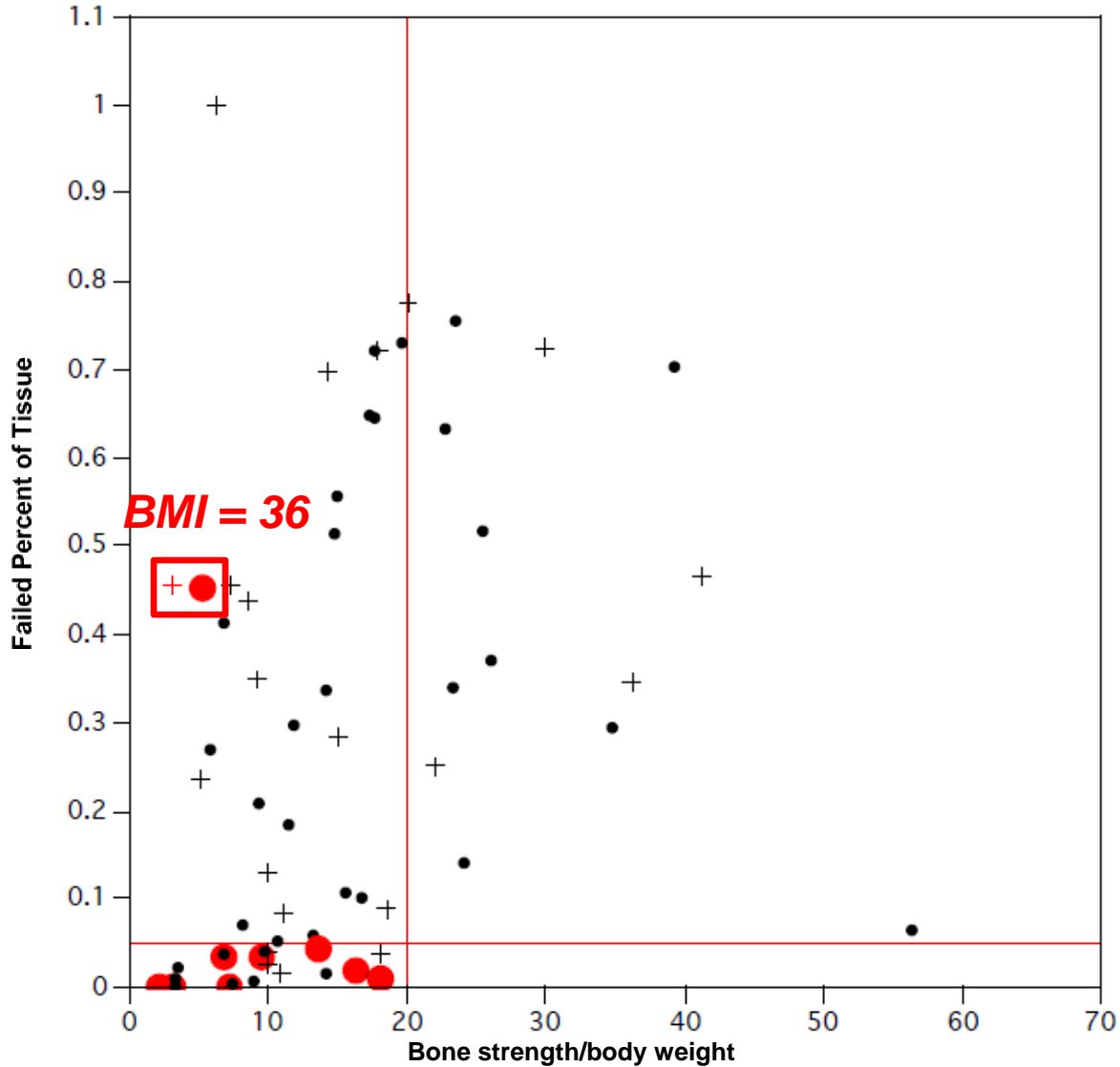


Results

- Patients with clinical events: 11 (16.7%)
 - 6 progressive malunions
 - 4 unanticipated bone graft
 - 1 refracture
- Virtual stress test data
 - Percent Area of Failed Tissue
 - Axial Compression



Results





Results

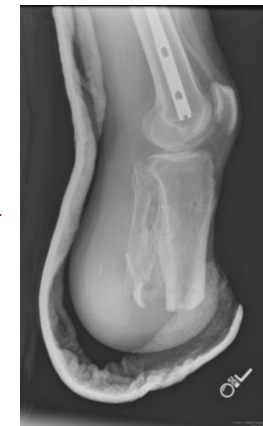
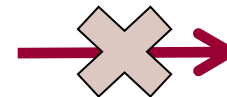
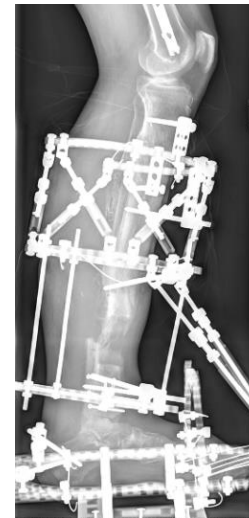Test Performance

- Sensitivity: 82% (9/11)
- Specificity: 76% (42/55)
- Positive predictive Value:
41% (9/22)
- Negative predictive value:
95% (42/44)
- Cohen's Kappa: 0.416 ± 0.11

	Clinical Event	Successful Removal	Total
BCT Positive	9	13	22
BCT Negative	2	42	44
Total	11	55	

Discussion

- 16% Rate of clinical events
 - Keeling et al: 5/38 (13%)
 - Atesalp et al: 14/163 (8.5%)
- Identified 9 of 11 clinical events
 - Cost effectiveness
 - Mental toll of treatment failure
- Limitations
 - Retrospective
 - Objective outcome
 - Military patients
 - 100% Captured, High-demand
 - Small number
 - Multicenter grant application



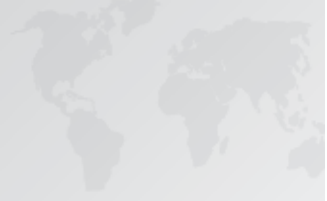Keeling, J.J., D.E. Gwinn, S.M. Tintle, R.C. Andersen, and F.X. McGuigan, Short-term outcomes of severe open wartime tibial fractures treated with ring external fixation. *J Bone Joint Surg Am*, 2008. 90(12): p. 2643-51.

Atesalp AS, Yildiz C, Basbozkurt M, Gür E. Treatment of type IIIa open fractures with Ilizarov fixation and delayed primary closure in high-velocity gunshot wounds. *Mil Med*. 2002;167:56-62.



Conclusion

Refinement of CT-derived virtual stress testing and eventual application into clinical decision making at the time of frame removal may improve outcomes and reduce morbidity



Thank you